

BRIARPOINTE VETERINARY CLINIC

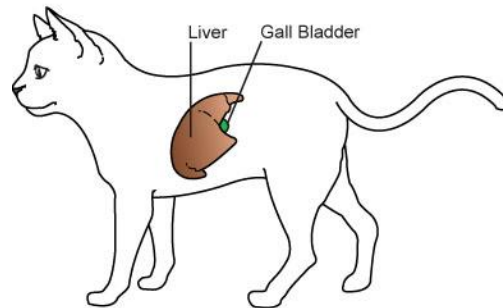
47330 Ten Mile Road
Novi, MI 48374
(248) 449-7447

Ronald A. Studer, D.V.M., L.P.C. John S. Parker, D.V.M.

CHOLANGIOHEPATITIS IN CATS

What is cholangiohepatitis?

Cholangitis is a term referring to inflammation of the bile duct. Cholangiohepatitis means inflammation of the bile ducts, gall bladder and surrounding liver tissue. The gall bladder secretes bile which is a substance involved in digestion. If bile production is reduced or if bile cannot enter the digestive tract through the bile ducts due to obstruction or swelling, illness occurs. Cholangitis and Cholangiohepatitis (CCHS) usually occur together in cats. CCHS is further classified as suppurative or nonsuppurative, granulomatous or lymphoproliferative, based on microscopic evaluation of the affected tissues (histopathology). CCHS is much more common in cats than dogs.



What causes CCHS?

There are numerous causes and contributory factors involved with CCHS. CCHS often has a preceding or coexisting condition such as inflammation of the bile ducts, gallstones, pancreatitis, inflammatory bowel disease (IBD), or chronic interstitial nephritis (a form of kidney disease). Many cases of CCHS are suppurative, caused by a bacterial infection of the gall bladder with subsequent obstruction of the bile duct from mineralized deposits or swelling. Nonsuppurative (sterile) CCHS may be caused by immune-mediated disease (a condition where the body attacks itself; in this case, the tissues of the gall bladder or bile ducts are attacked), by the formation of tissues that partially or completely block the bile ducts or by tumors. We will discuss the specifics of your cat's problem based on the results of diagnostic testing.

What are the clinical signs of cholangiohepatitis?

The clinical signs associated with CCHS are based on the type of CCHS present. In suppurative CCHS the clinical signs are more severe and sudden. Suppurative CCHS cases often have painful abdomens, a high fever, anorexia, collapse and vomiting. Cats may be jaundiced (yellowish discoloration of the skin, eyes, gums and mucous membranes).

Nonsuppurative CCHS cases have more ambiguous, chronic symptoms. These cats often experience periods of vague clinical illness such as lethargy, vomiting, anorexia, and weight loss. Most cases of nonsuppurative CCHS will have a normal physical examination. If the bile ducts become small as a result of CCHS, the cat may have an increased appetite since it is unable to properly digest foods.

How is CCHS diagnosed?



It is important to rule out other diseases that may be contributing to the clinical signs or causing CCHS. A thorough medical history and physical examination are the first step in diagnosing CCHS. If CCHS is suspected, blood and urine tests are performed. Thyroid hormone levels (thyroxin) are normally measured to rule out hyperthyroidism as a cause of elevated liver enzymes. Pancreatic function tests are often evaluated to search for underlying subclinical pancreatitis that may be causing CCHS. Abdominal radiographs are often performed but may appear normal even in cats with CCHS. Abdominal ultrasound is often recommended and is considered the best way to diagnose CCHS. Additionally, ultrasound-guided fine needle aspiration of the gall bladder is often done to evaluate the bile, look for abnormal cells or signs of infection. Other diagnostic tests include ultrasound-guided biopsy and exploratory surgery (laparotomy). Laparotomy is especially recommended in cases where bile duct obstruction is suspected.

What is the treatment of CCHS?

Treatment is based on clinical signs and the underlying cause. The initial treatment involves stabilizing the cat and providing supportive care such as intravenous fluids, feeding through a feeding tube, and antibiotics. Surgery may be required in cats with biliary duct obstruction. Additional drugs and therapies may be recommended based on your cat's specific condition.

What is the prognosis for a cat diagnosed with CCHS?

With suppurative CCHS, the prognosis is usually good that the condition may be cured. In nonsuppurative CCHS, chronic, long-term remission is the therapeutic goal. Prognosis is based on the severity and specific underlying cause or causes.